















A Comprehensive Review of Toxoplasmosis: Serious Threat to Human Health

Aswin Rafif Khairullah¹ , Shendy Canadya Kurniawan² , Agus Widodo³ , Mustofa Helmi Effendi^{4,*} , Abdullah Hasib⁵ , Otto Sahat Martua Silaen⁶ , Sancaka Chasyer Ramandinianto⁷ , Ikechukwu Benjamin Moses⁸ , Katty Hendriana Priscilia Riwu⁹ , Sheila Marty Yanestria¹⁰ , Muhammad Esa Erlang Samodra¹¹  and Daniah Ashri Afnani¹² 

¹Division of Animal Husbandry, Faculty of Veterinary Medicine, Universitas Airlangga. Jl. Dr. Ir. H. Soekarno, Kampus C Mulyorejo, Surabaya 60115, East Java, Indonesia

²Master Program of Animal Sciences, Department of Animal Sciences, Specialisation in Molecule, Cell and Organ Functioning, Wageningen University and Research, Wageningen 6708 PB, Netherlands

³Department of Health, Faculty of Vocational Studies, Universitas Airlangga. Jl. Dharmawangsa Dalam Selatan No. 28-30, Kampus B Airlangga, Surabaya 60115, East Java, Indonesia

⁴Division of Veterinary Public Health, Faculty of Veterinary Medicine, Universitas Airlangga. Jl. Dr. Ir. H. Soekarno, Kampus C Mulyorejo, Surabaya 60115, East Java, Indonesia

⁵School of Agriculture and Food Sustainability, The University of Queensland. Gatton, QLD, 4343, Queensland, Australia

⁶Doctoral Program of Biomedical Science, Faculty of Medicine, Universitas Airlangga. Jl. Dr. Ir. H. Soekarno, Kampus C Mulyorejo, Surabaya 60115, East Java, Indonesia

⁷Division of Veterinary Clinic, Faculty of Veterinary Medicine, Universitas Airlangga. Jl. Dr. Ir. H. Soekarno, Kampus C Mulyorejo, Surabaya 60115, East Java, Indonesia

⁸Department of Applied Microbiology, Faculty of Science, Ebonyi State University. Abakaliki 480211, Nigeria

⁹Department of Veterinary Public Health, Faculty of Veterinary Medicine, Universitas Mataram. Jl. Majapahit No.62, Gomong, Mataram 83115, Nusa Tenggara Barat, Indonesia

¹⁰Faculty of Veterinary Medicine, Universitas Wijaya Kusuma Surabaya. Jl. Dukuh Kupang XXV No.54, Dukuh Kupang, Dukuh Pakis, Surabaya 60225, East Java, Indonesia

¹¹Bachelor Program in Veterinary Medicine, Faculty of Veterinary Medicine, Universitas Airlangga. Jl. Dr. Ir. H. Soekarno, Kampus C Mulyorejo, Surabaya 60115, East Java, Indonesia

¹²Master Program in Veterinary Disease and Public Health, Faculty of Veterinary Medicine, Universitas Airlangga. Jl. Dr. Ir. H. Soekarno, Kampus C Mulyorejo, Surabaya 60115, East Java, Indonesia

Abstract:

Toxoplasmosis is a parasitic disease caused by *Toxoplasma gondii*. Despite infecting a major fraction of the global population, *T. gondii* rarely results in clinically significant disease. Cats are the only known definitive host for this parasite, which sheds millions of oocysts in its feces every day, which then sporulate and become infective in the environment. This comprehensive review article aims to explain the etiology, pathogenesis, epidemiology, transmission, clinical symptoms, diagnosis, risk factors, public health importance, economic effect, treatment, and prevention of toxoplasmosis. A search for various publications in English with the criteria of reviewing articles explaining toxoplasmosis was carried out. *T. gondii* reproduces through two life cycles, namely the sexual cycle and the asexual cycle. In general, consuming parasite cysts in tainted food or water is how humans and other warm-blooded animals become infected with *T. gondii*. Nearly every region of the world has reported incidences of toxoplasmosis in humans, and around one-third of people are susceptible to latent infection. According to the reports, the main ways through which diseases spread are by water, tainted food, eating tissue cysts or oocysts, and congenital transmission. Infected individuals may experience asymptomatic cervical lymphadenopathy during an acute systemic infection. Diagnostic evaluation is very important for early detection, prevention of transmission, and as a reference for treatment options for infected pregnant women. Consuming undercooked meat is traditionally seen as a significant risk factor for developing toxoplasmosis. The impact of toxoplasmosis is very significant in humans because it causes abortion and disease in newborns, resulting in serious economic losses. To treat toxoplasmosis, dihydropteroate synthetase and dihydrofolate reductase inhibitors are advised. Toxoplasma transmission to humans can be avoided by thoroughly washing your hands with soap after handling meat, poultry, or shellfish.

Keywords: Toxoplasmosis, *Toxoplasma gondii*, Cat, Maternal health, Human health, Parasite.

© 2024 The Author(s). Published by Bentham Open.

This is an open access article distributed under the terms of the Creative Commons Attribution 4.0 International Public License (CC-BY 4.0), a copy of which is available at: <https://creativecommons.org/licenses/by/4.0/legalcode>. This license permits unrestricted use, distribution, and reproduction in any medium, provided the original author and source are credited.



Received: October 20, 2023
Revised: January 20, 2024
Accepted: January 23, 2024
Published: February 12, 2024

*Address correspondence to this author at the Division of Veterinary Public Health, Faculty of Veterinary Medicine, Universitas Airlangga. Jl. Dr. Ir. H. Soekarno, Kampus C Mulyorejo, Surabaya 60115, East Java, Indonesia;
E-mail: mhelmeffendi@gmail.com

Cite as: Khairullah A, Kurniawan S, Widodo A, Effendi M, Hasib A, Silaen O, Ramandinianto S, Moses I, Riwu K, Yanestria S, Samodra M, Afiani D. A Comprehensive Review of Toxoplasmosis: Serious Threat to Human Health. Open Public Health J, 2024; 17: e18749445281387. <http://dx.doi.org/10.2174/0118749445281387240202094637>



Send Orders for Reprints to
reprints@benthamscience.net

1. INTRODUCTION

A zoonotic condition called toxoplasmosis is caused by the protozoan parasite *Toxoplasma gondii* [1]. This species belongs to the phylum of Apicomplexa intracellular coccidian parasite [2]. This parasite is typically spread by animals, including domestic pets like dogs, cats, and birds, as well as livestock like pigs, cows, goats, and sheep [3]. This parasite is found throughout the world [4]. It is a parasite with characteristics resembling the malaria-causing disease [5]. Despite infecting a major fraction of the global population, *T. gondii* rarely results in clinically significant disease [6]. Although toxoplasmosis is typically asymptomatic, it can become serious and even fatal during pregnancy when it affects the fetus, the infant, and people with compromised immune systems [7]. The majority of toxoplasmosis cases in immunocompetent people are benign or subclinical [8]. Individuals with immunodeficiency and congenital forms of the condition experience the most severe symptoms [9].

T. gondii is a parasite that is extensively researched due to its value in medicine and veterinary science, as well as its appropriateness as a model for cell biology and molecular investigations with unicellular organisms [10]. The name *Toxoplasma gondii* comes from the Greek words toxon (arc) and plasma (shape), while gondii comes from the rodent *Ctenodactylus gundi*, which was first isolated in 1908 [11]. There are various kinds, such as oocysts, tachyzoites, and cysts [12]. This parasite lacks host specificity and has a universal nature [13]. While it only infects cats during the sexual stage, it can parasitize any mammals during the asexual stage, including humans and cats [14]. The wide variety of warm-blooded mammalian hosts, including the risk of infection in a third of the global human population, makes *T. gondii* the most feared parasitic organism worldwide [15].

The prevalence of the disease varies significantly worldwide [16]. For instance, toxoplasmosis prevalence can reach approximately 90% in specific demographic groups in highly endemic areas, such as portions of Africa, whereas it might reach 60% in some communities in Europe [17]. Cats are the only known definitive hosts for this parasite, shedding millions of oocysts in their feces every day, which then sporulate and become infective in the environment [18]. Although oocyst shedding in domestic cats only happens 1-3 weeks after the first infection, it may occasionally occur throughout a cat's

lifetime in feral cats [19]. The two primary horizontal routes of transmission are ingestion of these sporulated oocysts, which infect plants, soil, and water supplies, or intake of bradyzoites from raw or undercooked meat [20].

Meat, which is raw or undercooked, with *Toxoplasma* cysts or oocysts can transmit the disease [21]. These cysts are resistant to stomach acid when swallowed, and the parasite is prepared to infect if swallowed [22]. It is possible that a pregnant woman who has toxoplasma will pass it on to the fetus through the placenta without exhibiting any clinical symptoms; nevertheless, the symptoms will emerge after the baby is born [23]. Infection in ruminant animals is thought to be spread through cat feces-contaminated food and insect vectors, such as flies and cockroaches [3]. The disease can also spread through the mucous membranes of infected hosts through inhalation, saliva, mucus, feces, and milk from patients [17]. When this disease breaks out, immunocompromised adults experience acute and sporadic symptoms. People with impaired immune systems, such as those with HIV/AIDS, experience severe outbreaks (after the reactivation of bradyzoites into disseminated tachyzoites) [24].

The clinical manifestations of this illness are persistent and subclinical for the duration of the infection [25]. Due to the fact that toxoplasmosis does not always result in pathological conditions in the host, especially in patients with strong body immunity, many infected people are unaware that they are infected [26]. The most obvious symptom is if this infection develops during pregnancy, which increases the risk of miscarriage, stillbirth, live delivery with birth defects, such as hydrocephalus or microcephalus, motor difficulties, retinal and brain damage, as well as indicators of mental disorders [27]. In addition, prenatal infection caused by toxoplasmosis might result in chorioretinitis in people [28]. The onset of clinical signs includes fever, malaise, soreness in the muscles, pneumonia, inflammation of the meninges of the brain, and psychomotor abnormalities [8].

Toxoplasmosis infections are recognized as a concern and a serious public health issue due to the great prevalence of transmission in humans, the chronic nature of the disease, its potentially lethal effects, and the fact that many people are unaware they have the infection [29]. This comprehensive review article aims to explain the etiology, pathogenesis, epidemiology, transmission,

clinical symptoms, diagnosis, risk factors, public health importance, economic impact, treatment and prevention of toxoplasmosis. The scientific literature that the public can utilize to prepare for toxoplasmosis is provided by the data gathered through this review.

2. ETIOLOGY

In 1908, Nicole and Manceaux made the initial discovery of *T. gondii* in rats (*Ctenodactylus gundi*) in Africa [30]. *T. gondii* belongs to the Genus *Toxoplasma*, Subfamily Toxoplasmatinae, Family Sarcocystidae, Subclass Coccidia, Class Sporozoa, and Phylum Apicomplexa [31]. The first form is a trophozoite, which contains a crescent-shaped nucleus with a karyosome in the middle and is 4-6 microns in length and 2-3 microns in breadth [2]. When stained with Romanowsky's stain, the nucleus will be red, while the cytoplasm will be pale blue. The second form, bradyzoites, a stage of chronic toxoplasmosis, divide slowly in tissue cysts while doing endogenous division in cysts [32]. Tissue cysts are found in chronic or asymptomatic infections in the brain, skeletal

muscle, and heart [29]. These cysts, which can hold up to 60,000 bradyzoites, can persist in the tissue for several days after the host has passed away [33]. The third form, oocysts, which are typically discharged in the cat's feces and are located in the cat's intestines, particularly those that have sporulated (contain sporozoites), can endure temperatures of 24°C for 10 months or 37°C for 28 days [34]. The life cycle of *T. gondii* is shown in Fig. (1).

T. gondii reproduces through two life cycles, namely the sexual cycle and the asexual cycle [1]. The asexual cycle occurs in hosts between humans and warm-blooded animals, such as birds, but the sexual (enteroepithelial) cycle occurs in true hosts, such as cats [35]. The asexual stage begins with the ingestion of infective cysts or oocysts by the true host (cats eat mice containing the first or third forms of *T. gondii*) [36]. The time needed for *T. gondii* to develop from the bradyzoite prepatent stage (second form) is 3-10 days, but the time needed for tachyzoites (first form) is 5-10 days, and the third form takes 24 days or longer to develop into oocysts [18].

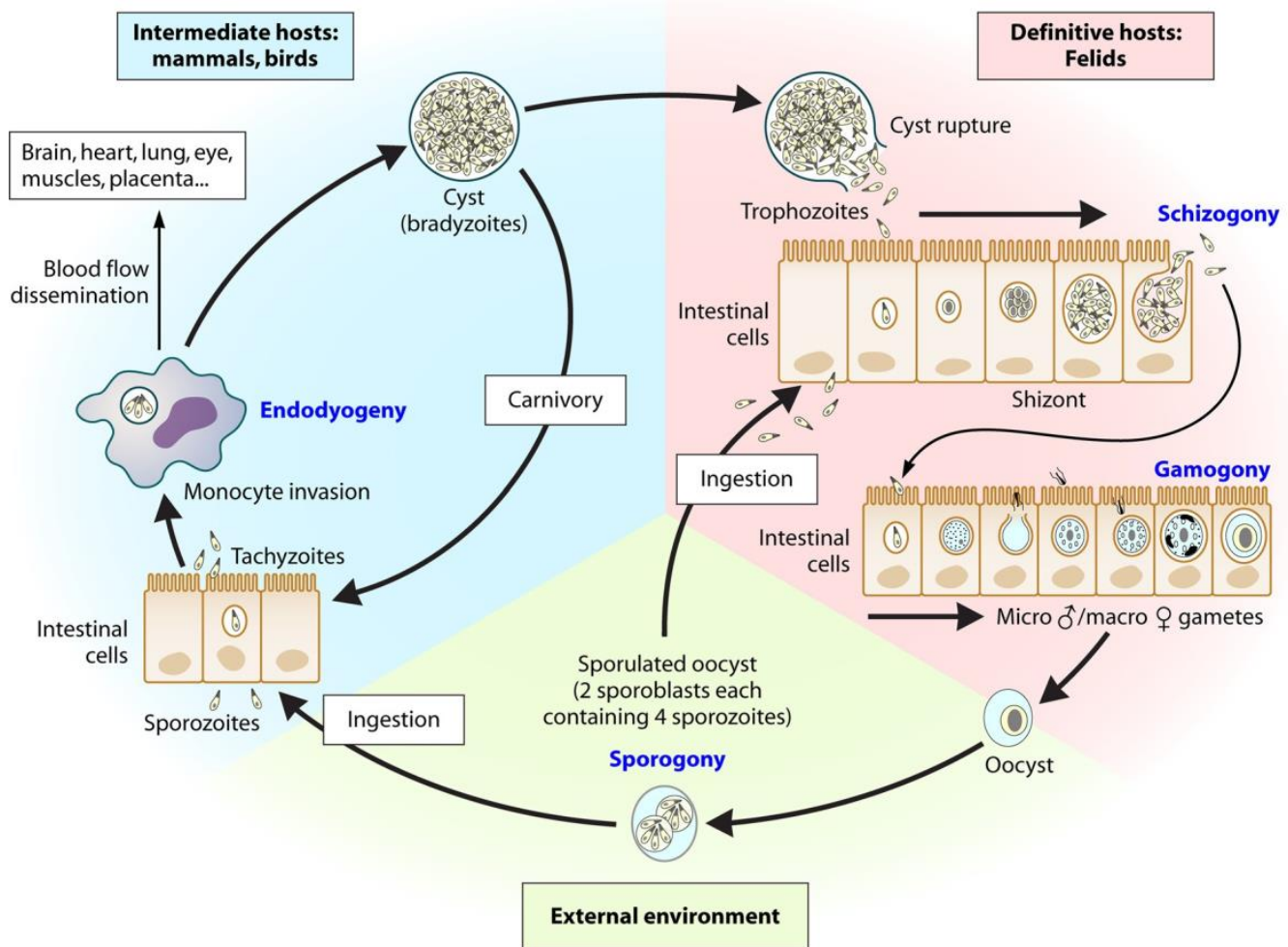


Fig. (1). The life cycle of *T. gondii* [17].

The five forms of bradyzoite and tachyzoite cysts that form are types A, B, C, D, and E, each of which differ in the number of organisms present and in the way those organisms divide [37]. Type A, which first manifests 12 to 18 hours after infection and is the smallest division, seems to have two or three organisms in the small intestine [38]. Type B, which appears 12-54 hours after infection, contains a primary nucleus in the center [39]. Type C, which is separated into schizogony and occurs 24 to 54 hours after infection, is made up of endodiogeny and endopolygeny [40]. This type has a subterminal nucleus. Type D occurs from 3-15 days after infection, and according to Hatter *et al.* [41], a total of 90% of toxoplasma is found in the small intestine at that time. Type D is smaller than type C and is divided into endodiogeny and schizogony [18]. Type E is divided into schizogony, which occurs 3-15 days after infection and is similar to type D [39].

The sexual stage begins with the development of merozoites into macrogametes and macrogametes in the intestinal epithelial cells. The two gametes undergo a fertilization process, and a zygote is formed, which then grows into an oocyst [42]. Oocysts pass out with the feces after entering the intestinal lumen [43]. The oocysts either sporulate or become infectious after 2-3 days at 24°C [44].

This cycle occurs concurrently with the cycle in the epithelium of the intestinal cells of the actual host and is the subsequent life cycle that takes place outside the intestinal tissue of the true host, particularly in the intermediate host [45]. The tachyzoites that are produced after oral infection develop into vacuoles of various types of cells that are targeted [46]. Then, eight or more tachyzoites are built up in cells; this is known as pseudocyst [47]. When a pseudo-cyst ruptures, tachyzoites attack the surrounding cells and spread throughout the body through the blood and lymph flow [48]. Tachyzoites will be eliminated by the body's immunity, with the exception of those that have evolved into bradyzoites in tissue cysts, such that parasitemia may repeat multiple times until antibodies are generated in the plasma [32]. Tissue cysts are found as early as the eighth day following the host's first infection, and they can endure for the duration of the host's life [49]. A repeat of the acute Toxoplasma infection could occur if bradyzoites are released and grow into tachyzoites as the body's immunity declines [50].

3. PATHOGENESIS

In general, consuming parasite cysts in tainted food or water is how humans and other warm-blooded animals become infected with *T. gondii* [51]. *T. gondii* lacks the specialized organelles needed for mobility during its voyage, such as cilia or flagella [52]. This parasite will move with the actin-myosin motor complex [53]. *T. gondii* can move in three different ways: helical motion, circular motion, and spiral motion [54]. The parasite can advance by helical movement [55]. This parasite's cytoskeleton is made up of adhesins that are secreted from micronemes, which are apical organelles [56]. *T. gondii* can migrate

more easily because of this micronema protein's attachment to host cells [57].

Following ingestion, the stomach of the host breaks down the *T. gondii* cyst wall and produces bradyzoites, which are immune to the gastric peptide enzyme [58]. This parasite can, therefore, enter the small intestine. *T. gondii* will develop into tachyzoites in the small intestine, reproduce inside the cells to create parasitoporous vacuoles, and then start to infect the neighboring cells [59]. Soedarto (2012) demonstrated that parasitoporous vacuoles can quickly enter host cells [60]. The host's surface cells and the parasite's walls are only loosely connected [61]. This weak affinity is mediated by surface proteins from parasites called SAGs (surface antigens), SRSs (SAG-related sequences), and SUSAs (SAG-unrelated surface antigens) [62]. More than one host molecule is thought to have a role in mediating this attachment to host cells [61]. Although specific receptors have not been found on host cells, it is suspected that laminin, lectin, and SAG1 play a role in the attachment and entry of tachyzoites [63].

After piercing the intestinal epithelial layer in the small intestine, tachyzoites will go to the lamina propria [49]. Tachyzoites in the lamina propria cause a potent immunological response that includes polymorphonuclear neutrophils, monocytes, and dendritic cells [64]. This immune reaction will kill certain parasites, while others will continue to multiply in cells [65]. Parasites that grow in cells travel through the intestinal lymphatics to the lymph nodes [66]. Additionally, tachyzoites will be spread via the transendothelial migration (TEM) mechanism in conjunction with blood flow through lymph flow [67]. The organs and tissues of the host's body with nuclear cells can eventually become infected with *T. gondii* [68].

Seven days after infection, cysts start to grow in tissue and last for the duration of the host's life [18]. These tachyzoite cysts will proliferate and form necrosis [69]. The tachyzoites will be removed from the host's tissue if the immune reaction is effective [32]. However, if the host's immune system is weak or compromised, an acute infection will develop, progress, and perhaps result in clinical symptoms [70]. These clinical symptoms differ in each tissue and might cause significant damage by triggering an inflammatory response [71].

4. EPIDEMIOLOGY

Toxoplasmosis infection has been reported in warm-blooded animals and humans, and its spread has been reported throughout the world [1]. Almost every species, including mammals and various bird species, is affected by this disease [72]. Nearly every region of the world has reported incidences of toxoplasmosis in humans, and around one-third of people are susceptible to latent infection [17]. The incidence of toxoplasmosis in developing and underdeveloped countries is reported to be very high, but it has been found that the transmission rate is low in developed countries [6]. Africa, the Middle East, Southeast Asia, Central Europe, Latin America, and Eastern Europe are among the regions with the highest recorded rates of toxoplasmosis [38]. Toxoplasmosis rates

in the US range from 15 to 22%, and the current percentage is lower than in prior years [73]. In Europe, a similar pattern is also present [74]. Its prevalence can be affected by a number of elements, including culture, environment, ethical standards, and the presence of cats [75].

According to Shapiro *et al.* [20], oocysts have a high percentage of environmental survival. Due to the chilly climate, toxoplasmosis is extremely rare in European countries and more common in warm climates [1]. The frequency of toxoplasmosis in cats is estimated to be around 40% based on climatic factors; however, it drops to 16.1% in the southwest and reaches a high of 59.2% in Hawaii [76]. Food preparation habits, such as undercooked or undercooked food, are important factors that influence transmission [77]. Consuming raw shellfish and oysters has been identified as a significant risk factor for the spread of toxoplasmosis in a number of nations [78]. *T. gondii* infection affects between 25 and 30% of the world's population [79]. Many climatic factors influence oocyst survival rates, and ruminants play an important role in disease transmission [3].

Additionally, it appears that seroprevalence is higher in older adults, depending on the socioeconomic circumstances of the individuals [80]. Water containing oocysts, drinking unfiltered water, or drinking water in recreational facilities all help spread this illness [81]. The incidence of toxoplasmosis infection is influenced by socioeconomic status [82]. In Brazil, the upper socioeconomic group has a seroprevalence of 23%, the middle socioeconomic group 62%, and the bottom socioeconomic group 84% [83]. Unfiltered water consumption raises the possibility of contracting *Toxoplasma* [84]. These analyses are especially important in underdeveloped and underprivileged countries [85]. However, toxoplasmosis infection is predominantly linked to poverty in the United States [86]. Additionally, different communities in the US have different rates of toxoplasmosis infections [17].

Over the past 20 years, toxoplasmosis rates have decreased in many nations due to improvements in socioeconomic situations, drinking water quality, hygiene standards, consumption of frozen meat, modifications to livestock systems, and feeding autoclaved food to cats [87]. Infections with *T. gondii* were found in 14.1% of US citizens between the ages of 12 and 49 from 1988 to 1994. However, they dropped by 9% between 1999 and 2004 [1]. In France, toxoplasmosis infected around 80% of expectant mothers in the 1960s, but that number fell by 44% by 2003 [23]. There are reports of this declining trend in practically all of the European nations [88]. In the Netherlands, women of reproductive age experienced a 50% decline in the disease's seroprevalence between 1995 and 2007 [89].

5. TRANSMISSION

According to reports, the main ways that diseases are spread include water, tainted food, eating tissue cysts or oocysts, and congenital transmission [87]. However, this disease's spread throughout groups varies significantly,

largely depending on dietary and behavioral patterns [90]. Unpasteurized milk can cause infection, and tachyzoites can contaminate blood [91]. The majority of intermediate hosts are tissue cysts found in the muscles and brain [32]. As hosts for the continuation of sexual reproduction, enteroepithelial cycling, and oocyst formation, cats have been documented to contract toxoplasmosis from infected prey, such as birds or rodents [39]. Carnivorous animals from wild habitats, such as skunks, foxes, raccoons, and bears, also contract toxoplasmosis by consuming cysts from tissue [92]. Consuming tainted uncooked meat, such as lamb or pork, causes toxoplasmosis in humans [93]. Numerous proteolytic enzyme activities in the stomach of the host break down ingested tissue cysts, releasing parasites in the form of bradyzoites [58]. This parasite is shown to be extremely protease-resistant and persists in the small intestine of the host organism [94]. According to one study, within two weeks of consumption, more than 10 million cysts are expelled in cat feces [95]. Oocysts that have been released into the environment will sporulate within five days [20]. These sporulating organisms persist in soil samples for almost a year [96].

A primary risk factor for spreading toxoplasmosis is generally eating vegetables, fruits, or anything that has been infected with oocysts [97]. Prior reviews of these risk variables and transmission methods were carried out by Ebrahimi *et al.* [98]. Infections from oocysts in people are more severe and complex than infections from cysts [99]. However, it has been observed that waterborne infections are sporadic [20]. In the US, toxoplasmosis outbreaks have been associated with marine animal contact, while in Canada, outbreaks of the disease have been linked to oocyst contamination of municipal water reservoirs [100]. Cats shed their oocysts over a short period of time, and despite their non-infectious oocyst shedding, direct contact with cats does not increase the chance of contracting a cat infection [101]. Oocysts remained persistent for six months in seawater, demonstrating that coastal habitats are a significant source of infection [102]. Additionally, oocysts switch between hosts [103]. Fish like sardines and anchovies, which are filter feeders, contain oocysts that can tolerate a variety of conditions and continue to survive [104].

There have also been reports of congenital transmission, which happens when toxoplasmosis is in the acute phase [105]. Tachyzoites, which are parasites from the mother that cross the placenta and infect the fetus, are contagious [106]. Based on the stage of pregnancy, maternal toxoplasmosis has different effects [23]. Maternal toxoplasmosis levels are very low during the first trimester of pregnancy, but as the pregnancy progresses, the transmission rate rises to about 80% [107]. Early maternal toxoplasmosis is associated with a number of issues, including mental impairment, hydrocephalus, and spontaneous abortion [108]. However, the transmission rate is particularly high during the final trimester, and children have been documented to experience a variety of subclinical interventions, including recurrent chorioretinitis and subclinical interventions that may result in

blindness or vision issues [109]. According to earlier research by Galvan-Ramírez *et al.* [110], congenital toxoplasmosis affects about 1 in 1000 to 1 in 10,000 newborns in most population groups. In a study, Faral-Tello *et al.* [111] employed PCR to identify vertical transmission through umbilical cord tissue, and the transmission rate was close to 19.8%. The transmission rate is roughly 75% in mouse models; however, it has been noted to drop to 65% in sheep [112]. These results suggest that the degree of vertical transmission in humans is not yet fully understood because the majority of investigations only employ serological techniques. Oocysts are abundant in a wide range of habitats, so it is crucial to examine oocysts in the environment to determine health concerns [113]. Recent research demonstrates that oocysts contaminate marine, aquatic, and terrestrial habitats [114]. Environmental and geological factors like soil texture, temperature, and chemistry have a major impact on *T. gondii* oocyst survival [75]. There is a dearth of information on oocyst survival rates, persistence in soil samples, and pathogen traits, including tissue cyst infectivity.

6. CLINICAL SYMPTOMS

The majority of immunocompetent people would not experience symptoms for the rest of their lives, although both competent and immunocompetent people can contract the illness, particularly retinochoroiditis [115]. Infected individuals may experience asymptomatic cervical lymphadenopathy during acute systemic infection, as well as signs and symptoms that resemble infectious mononucleosis, such as myalgia, sore throat, myocarditis, maculopapular rash, fever, meningitis, polymyositis, muscle pain, malaise, pneumonia, and psychomotor disorders [8].

6.1. Ocular Toxoplasmosis

Ocular toxoplasmosis (OT) frequently results in distinctive, localized, white-appearing retinal lesions that are typically smaller than 1,000 microns [116]. A significant vitreous inflammatory response gives the unmistakable “headlights in the fog” image [117]. These lesions are caused by immune reactions against the parasite and direct parasitic tissue invasion [118]. Active lesions are frequently accompanied by nearby old scars [119]. The clinical indicators and illness presentation of patients with AIDS varied significantly, and other infectious diseases, such as cytomegalovirus, chorioretinitis, and syphilitic retinitis, should be considered in the differential diagnosis [29].

During primary or recurrent eye infections, retinochoroidal inflammation typically lasts for 2 to 4 months [119]. Nearly one in four patients with active OT lesions experienced blindness in at least one eye and one in five patients experienced a recurrence, especially in eyes that had previously experienced retinal scarring, according to an observational case series of 154 patients with active OT lesions who were monitored for at least five years [120]. People over the age of 40 and those who were exposed to the parasite within the first five years of their recovery

have a higher risk of developing OT again [121].

6.2. Toxoplasmic Encephalitis

Toxoplasmic encephalitis (TE), which is typically caused by the reactivation of latent infections, continues to be a significant source of morbidity and mortality in AIDS patients, even in the era of highly active antiretroviral therapy [122]. Particularly in areas where the disease is more prevalent, like South America, TE should be suspected since it can present with a wide range of nonspecific symptoms, including dementia, ataxia, lethargy, and seizures [123].

The most distinguishing sign of *T. gondii* infection in AIDS patients, although it is not pathognomonic, is the appearance of numerous brain abscesses [124]. Although the basal ganglia and corticomedullary junction are the most often infected areas of the brain with *T. gondii*, postmortem brain examination shows that both hemispheres are involved globally [125].

6.3. Congenital Toxoplasmosis

Congenital toxoplasmosis in newborns can be asymptomatic or cause retinochoroiditis and CNS involvement [126]. Congenital toxoplasmosis is thought to affect 1-10 out of every 10,000 live births in the United States, 770 live births in Brazil, and 3,000 live births in France [67]. The burden of this disease in the Netherlands, however difficult to calculate, is roughly 620 disability-adjusted people each year, primarily because of retinal disease and fetal death [127]. This burden is equivalent to the widespread and frequent foodborne pathogen *Salmonella spp* [128].

The infection is typically more severe if transmitted early in pregnancy, but the danger of vertical transmission is higher in the latter stages of pregnancy [27]. The infection's most obvious symptom is when it affects a pregnant woman, which increases the risk of abortion, stillbirth, live births with malformations, such as hydrocephalus or microcephalus, motor difficulties, retinal and brain damage, and indicators of mental disorders [106]. Ultrasonography may be used to find and diagnose intracranial calcifications [129]. Epilepsy and delayed mental development are among the clinical signs and symptoms, which are comparable to those of other complex congenital illnesses like rubella, CMV, and the herpes simplex virus [130].

Congenital OT is generally more sight-threatening than acquired infections because the retinal lesions found in congenitally infected newborns are often located in the macula, the region responsible for central vision, and children who experience blindness or nearsightedness due to toxoplasmosis will remain disabled for years [117].

In contrast to other countries, where rates are significantly higher, congenital toxoplasmosis affects about 9% of children with serious visual impairment in the United States [131]. In Europe, 29% of children experience visual impairment, compared to 87% of children in Brazil, within three to four years of birth [132].

7. DIAGNOSIS

Diagnostic evaluation is very important for early detection, prevention of transmission, and as a reference for treatment options for infected pregnant women [133]. Although not routinely performed, diagnostic testing includes maternal serum sampling, the use of early fetal ultrasound, and amniocentesis [23]. Maternal examinations are performed periodically in high-risk settings, particularly in European nations [27]. Given that food intake has been established as a significant contributor to maternal infection, cultural behaviors involving food preparation and consumption are a significant element influencing the present transmission process [134]. In some nations, standardized newborn and mother screening procedures are infrequently used [135]. However, in order to prevent congenital infection, pregnant women who are in the high-risk category for getting toxoplasmosis must be examined [109].

The initial diagnostic procedure for identifying both present and historical infections is serological testing [136]. Serum markers identify the presence of immunoglobulin G (IgG) and immunoglobulin M (IgM) antibodies in maternal blood samples [137]. These antibody markers are indicative of *T. gondii* infection [138]. They can be detected using a variety of testing techniques, including dye tests, indirect fluorescent antibody tests, and enzyme immunoassay tests [139]. It is important to thoroughly evaluate IgM and IgG titers to differentiate between acute and chronic infections [140]. Five days to weeks after the initial exposure, IgM titers rise dramatically in response to acute illness [141]. Approximately one to two months later, the peak rise in IgM antibodies occurs [27]. One to two weeks after the first infection, IgG antibodies are typically found [142]. IgG titers increase for years after initial exposure [143].

The date of maternal infection is predicted by the presence of both serum antibodies [134]. There is no sign of infection in the mother if IgG and IgM markers are not found [144]. Persistent infection has been identified if the test reveals a positive IgG antibody marker with a negative IgM signal [138]. A new infection is believed to have occurred if both antibody markers are increased [145]. A repeat serum test is advised in situations of acute infection two to three weeks after the original findings [146]. Acute infection is indicated by a substantial rise in serum IgG antibody titer that is typically at least four times the baseline level [147]. The necessity of verifying a positive test through laboratory results arises from the prevalence of false positive results [133]. In nations that use serum testing, blood samples will still be taken for screening during the pregnancy even if the mother tests negative [148]. This screening technique enables early diagnosis in the mother and serves as a start toward therapy and prevention before the fetus undergoes seroconversion [136].

Amniocentesis can be carried out on pregnant patients whose toxoplasmosis test results are positive [149]. The ideal time to do an amniocentesis is no earlier than 18

weeks of pregnancy and four weeks following a suspected infection [109]. The high rate of false positive results and the significant risk of premature labor necessitate that amniocentesis is not to be carried out before 18 weeks [23]. *T. gondii* parasite detection in the amniotic fluid is necessary for the amniocentesis-based prenatal diagnosis of congenital toxoplasmosis [73]. Polymerase chain reaction (PCR) fluid testing is a popular diagnostic technique [150]. The positive predictive value of PCR testing is almost 100% [151]. Traditionally, fetal blood sampling *via* cordocentesis was once considered the gold standard of diagnostic testing [133]. Due to the increased fetal dangers of cordocentesis compared to amniocentesis, it is no longer practiced [149].

Fetal ultrasonography was used in the last diagnostic studies [27]. Ultrasound is recommended for women suspected of or diagnosed with an acute infection [144]. Fetal ultrasound checks for anomalies in the developing nervous system, kidneys, and liver [152]. Using ultrasound, it is possible to identify intracranial anomalies, such as hydrocephalus, ventriculomegaly, and intracerebral calcifications [109]. Along with the toxoplasmosis diagnosis, ultrasonography also reveals splenomegaly, congenital nephrosis, and ascites [153]. The prevalence of numerous fetal screening procedures is rising as a result of an increase in congenital toxoplasmosis presentations in neonates [107]. Fetal screening through neonatal screening is a process that is another detection approach in addition to newborn screening [154]. These screening techniques are crucial for detecting infants who are impacted; therefore, treating symptoms as they arise rather than taking preventative steps is necessary.

8. RISK FACTOR

Human infection is typically contracted by eating undercooked or raw meat that contains cyst tissue or by drinking water that has been contaminated with oocysts discharged by cats [97]. Consuming undercooked meat is traditionally seen as a significant risk factor for developing toxoplasmosis, particularly when it comes to lamb and hog [155]. Variations in *T. gondii* seroprevalence seem to be correlated with the food and hygiene practices of a population [156]. The prevalence of toxoplasmosis has decreased as a result of better farming techniques and improved public knowledge of the dangers of eating undercooked meat [157]. Transmission of *T. gondii* through organ transplantation from seropositive donors to seronegative recipients is an important potential cause of disease in heart, liver, kidney, and pancreas-liver transplant patients [158]. The epidemiology of this parasite has been expanded by the discovery of waterborne toxoplasmosis in humans [159]. There have not been any reports of transmission during nursing or direct human-to-human transmission other than from mother to fetus.

9. PUBLIC HEALTH IMPORTANCE

A zoonotic protozoan parasite called *T. gondii* affects almost all warm-blooded creatures, including humans,

domestic animals, and wild animals [1]. *T. gondii*-related human disease was first identified in the late 1930s [160]. According to reports, the rate of human infection varies worldwide [17]. Human toxoplasma infection can have catastrophic consequences, particularly for those with weakened immune systems, pregnant women, HIV/AIDS patients, youngsters, and those with co-occurring disorders [161]. The leading cause of death among AIDS patients is toxoplasmosis [29]. Infection during pregnancy can cause retinochoroiditis, hydrocephalus, intracranial calcification, and congenital infections of the fetus, in addition to abortion and other birth defects [162].

10. ECONOMIC EFFECT

The impact of toxoplasmosis is very significant in humans because it causes abortion and disease in newborns, resulting in serious economic losses [65]. There are several factors to take into account when analyzing the economic impact of disease. In addition to losses, the direct costs of disease also include the costs of treating affected animals and the costs of disease prevention [3]. Other factors are loss of expected output value and wastage of resources due to disease [163]. *T. gondii* is thought to be the primary cause of reproductive failure in commercial small ruminants like sheep and goats, and infections in these animals may be a significant factor in the parasite's transmission to humans [1].

Primary *T. gondii* infection is most likely to result in abortion in small ruminants that produce wool, milk, and meat [3]. Sheep that are congenitally infected are incapable of feeding themselves, have poor physical conditions, and lack muscle coordination [164]. Toxoplasmosis has a significant socioeconomic impact on human suffering and health care costs, particularly for children who are mentally retarded or blind [165]. Clinical illness often has a low incidence rate and occurs intermittently [166].

11. TREATMENT

To treat toxoplasmosis, dihydropteroate synthetase and dihydrofolate reductase inhibitors are advised [167]. One of the dihydrofolate reductase inhibitors used to effectively treat this disease is pyrimethamine [168]. Additionally, medications like sulfamethoxazole and trimethoprim are used to treat this infection [165]. Almost all medications that are prescribed work best against the tachyzoite stage rather than cysts that contain bradyzoites [169]. Cysts remain latent in the retina or uvea, and bradyzoite reactivation is frequently seen in immunocompetent patients [32]. Oocyst eradication using a reliable treatment has not been documented.

Treatment for toxoplasmosis, which can sometimes harm the eyes, includes the use of pyrimethamine together with clindamycin or sulfadiazine [170]. The combination of pyrimethamine and sulfadiazine is thought to be helpful in cases of immune system deterioration. Sulfadiazine coupled with pyrimethamine is an alternative to it [171]. Additionally advised for the treatment of this condition are medications like pyrimethamine and trimethoprim-

sulfamethoxazole [172]. In order to prevent parasite infections of host cells in immunocompromised hosts, vaccination is also advised [173]. Recombinant anti-Toxoplasma antibodies stop tachyzoite proliferation or early parasite invasion [174]. Although effective therapy has been reported, drug safety, duration of therapy, and drug potency are major concerns in the treatment of Toxoplasma infections [175]. Spiramycin is helpful for expecting mothers up until the 16th week of pregnancy, and different combinations of sulfadiazine, pyrimethamine, and folic acid are advised [176]. Spiramycin has been frequently utilized to lower mother-to-child transmission [177]. Neonatal infections are treated with pyrimethamine and sulfadiazine [178]. However, the effectiveness of the drug is still unclear. Pyrimethamine, sulfadiazine, and corticosteroids have been reported to be particularly efficient for treating ocular toxoplasmosis [179].

12. PREVENTION

Toxoplasma transmission to humans can be avoided by thoroughly washing your hands with soap after handling meat, poultry, or shellfish [20]. It is also advisable to wash with soap and water any cutting boards, sinks, knives, or other items that come into contact with raw meat [180]. Washing is efficient because *T. gondii* stages in meat can be eliminated by exposure to soap and water [181]. Extreme heat or cold can cause *T. gondii* organisms in meat to perish [22]. Meat tissue cysts can be eliminated by either heating it to 67°C or cooling it to -13°C [182]. Toxoplasma in tissue cysts is also killed by exposure to 0.5 kilorad gamma irradiation [162]. The meat of any animal should be cooked to 67°C before consumption, and tasting the meat while cooking or when seasoning should be avoided [10].

Pregnant women must refrain from handling cats, coming into contact with soil, and consuming raw meat [183]. To prevent the spread of this parasite, pet cats should only be fed dry, tinned, or cooked food [106]. Daily cat litter box emptying is recommended, and pregnant women should avoid this [27]. Due to the danger of coming into contact with cat excrement, gardening gloves should be worn [97]. Vegetables should be washed thoroughly before eating because there is a possibility of being contaminated with cat feces when harvested [184]. The hazards of toxoplasmosis must be understood by expectant mothers [162]. As of right now, people cannot be protected against toxoplasmosis using a vaccination [185].

Health professionals should advise women of childbearing age about the spread of *T. gondii* [186]. Pregnant women should learn about food safety and, if at all possible, avoid contact with cat excrement at their first prenatal appointment, according to health professionals [162]. The creation of toxoplasmosis vaccines has advanced significantly in recent years, and a veterinary vaccine based on the live attenuated S48 strain was created [187]. However, this vaccination is expensive, has side effects, and has a short shelf life [185]. Furthermore, this vaccination might produce pathogenic strains,

rendering it unfit for use in humans [46]. Numerous experimental experiments have demonstrated that it is feasible to create a vaccine to prevent human toxoplasmosis.

CONCLUSION

Toxoplasmosis is a dangerous threat to human health, especially for pregnant women. Diagnostic evaluation is very important for early detection, prevention of transmission, and, as a reference, treatment options for infected pregnant women. Currently, there is no vaccine to prevent toxoplasmosis in humans. Inhibitors of dihydrofolate reductase and dihydropteroate synthetase are recommended to treat toxoplasmosis. Washing your hands properly after handling meat, poultry or seafood with soap and water before performing other tasks will prevent the transmission of *Toxoplasma* to humans.

LIST OF ABBREVIATIONS

OT	=	Ocular Toxoplasmosis
TE	=	Toxoplasmic Encephalitis
PCR	=	Polymerase Chain Reaction

CONSENT FOR PUBLICATION

Not applicable.

FUNDING

This study was supported in part by the Skema Penelitian Unggulan Airlangga (PUA) Universitas Airlangga Year 2023, Number: 1710/UN3.LPPM/PT.01.03 /2023.

CONFLICT OF INTEREST

The authors declare no conflict of interest, financial or otherwise.

ACKNOWLEDGEMENTS

Declared none.

REFERENCES

- [1] S Al-Malki E. Toxoplasmosis: Stages of the protozoan life cycle and risk assessment in humans and animals for an enhanced awareness and an improved socio-economic status. *Saudi J Biol Sci* 2021; 28(1): 962-9. <http://dx.doi.org/10.1016/j.sjbs.2020.11.007> PMID: 33424388
- [2] Delgado ILS, Zúquete S, Santos D, Basto AP, Leitão A, Nolasco S. The apicomplexan parasite *Toxoplasma gondii*. *Encyclopedia* 2022; 2(1): 189-211. <http://dx.doi.org/10.3390/encyclopedia2010012>
- [3] Stelzer S, Basso W, Benavides Silván J, et al. *Toxoplasma gondii* infection and toxoplasmosis in farm animals: Risk factors and economic impact. *Food Waterb Parasitol* 2019; 15: e00037. <http://dx.doi.org/10.1016/j.fawpar.2019.e00037> PMID: 32095611
- [4] Ait Hamou S, Lamhamdi B, Hayah I, Belbacha I, Sadak A, Laboudi M. The level of knowledge about toxoplasmosis among university students in rabat in Morocco. *J Parasitol Res* 2021; 2021: 1-7. <http://dx.doi.org/10.1155/2021/5553977> PMID: 34350032
- [5] Spalenka J, Escotte-Binet S, Bakiri A, et al. Discovery of new inhibitors of *Toxoplasma gondii* via the pathogen box. *Antimicrob Agents Chemother* 2018; 62(2): e01640-17. <http://dx.doi.org/10.1128/AAC.01640-17> PMID: 29133550
- [6] Mose JM, Kagira JM, Kamau DM, Maina NW, Ngotho M, Karanja SM. A review on the present advances on studies of toxoplasmosis in eastern africa. *BioMed Res Int* 2020; 2020: 1-12. <http://dx.doi.org/10.1155/2020/7135268> PMID: 32724808
- [7] Pawelczyk A, Bednarska M, Caraballo Cortés K, et al. Seronegative infection with *Toxoplasma gondii* in asymptomatic human immunodeficiency virus type 1 (HIV-1)-infected patients and in blood donors. *J Clin Med* 2022; 11(3): 638. <http://dx.doi.org/10.3390/jcm11030638> PMID: 35160090
- [8] Layton J, Theiopoulou DC, Rutenberg D, et al. Clinical spectrum, radiological findings, and outcomes of severe toxoplasmosis in immunocompetent hosts: A systematic review. *Pathogens* 2023; 12(4): 543. <http://dx.doi.org/10.3390/pathogens12040543> PMID: 37111429
- [9] Avelino MM, Amaral WN, Rodrigues IMX, et al. Congenital toxoplasmosis and prenatal care state programs. *BMC Infect Dis* 2014; 14(1): 33. <http://dx.doi.org/10.1186/1471-2334-14-33> PMID: 24438336
- [10] Marin-García PJ, Planas N, Llobat L. *Toxoplasma gondii* in foods: Prevalence, control, and safety. *Foods* 2022; 11(16): 2542. <http://dx.doi.org/10.3390/foods11162542> PMID: 36010541
- [11] Weiss LM, Dubey JP. Toxoplasmosis: A history of clinical observations. *Int J Parasitol* 2009; 39(8): 895-901. <http://dx.doi.org/10.1016/j.ijpara.2009.02.004> PMID: 19217908
- [12] Álvarez García G, Davidson R, Jokelainen P, Klevar S, Spano F, Seeber F. Identification of Oocyst-driven *Toxoplasma gondii* infections in humans and animals through stage-specific serology-current status and future perspectives. *Microorganisms* 2021; 9(11): 2346. <http://dx.doi.org/10.3390/microorganisms9112346> PMID: 34835471
- [13] Sanchez SG, Besteiro S. The pathogenicity and virulence of *Toxoplasma gondii*. *Virulence* 2021; 12(1): 3095-114. <http://dx.doi.org/10.1080/21505594.2021.2012346> PMID: 34895084
- [14] Tong WH, Pavey C, O'Handley R, Vyas A. Behavioral biology of *Toxoplasma gondii* infection. *Parasit Vectors* 2021; 14(1): 77. <http://dx.doi.org/10.1186/s13071-020-04528-x> PMID: 33494777
- [15] Mendez OA, Koshy AA. *Toxoplasma gondii*: Entry, association, and physiological influence on the central nervous system. *PLoS Pathog* 2017; 13(7): e1006351. <http://dx.doi.org/10.1371/journal.ppat.1006351> PMID: 28727854
- [16] Montazeri M, Mikaeili Galeh T, Moosazadeh M, et al. The global serological prevalence of *Toxoplasma gondii* in felids during the last five decades (1967-2017): A systematic review and meta-analysis. *Parasit Vectors* 2020; 13(1): 82. <http://dx.doi.org/10.1186/s13071-020-3954-1> PMID: 32066495
- [17] Robert-Gangneux F, Dardé ML. Epidemiology of and diagnostic strategies for toxoplasmosis. *Clin Microbiol Rev* 2012; 25(2): 264-96. <http://dx.doi.org/10.1128/CMR.05013-11> PMID: 22491772
- [18] Attias M, Teixeira DE, Benchimol M, Vommaro RC, Crepaldi PH, De Souza W. The life-cycle of *Toxoplasma gondii* reviewed using animations. *Parasit Vectors* 2020; 13(1): 588. <http://dx.doi.org/10.1186/s13071-020-04445-z> PMID: 33228743
- [19] Zhu S, Shapiro K, VanWormer E. Dynamics and epidemiology of *Toxoplasma gondii* oocyst shedding in domestic and wild felids. *Transbound Emerg Dis* 2022; 69(5): 2412-23. <http://dx.doi.org/10.1111/tbed.14197> PMID: 34153160
- [20] Shapiro K, Bahia-Oliveira L, Dixon B, et al. Environmental transmission of *Toxoplasma gondii*: Oocysts in water, soil and food. *Food Waterb Parasitol* 2019; 15: e00049. <http://dx.doi.org/10.1016/j.fawpar.2019.e00049> PMID: 32095620
- [21] Đurković-Đaković O. Toxoplasmosis as a food-borne infection. *IOP Conf Ser Earth Environ Sci* 2017; 85: 012005. <http://dx.doi.org/10.1088/1755-1315/85/1/012005>
- [22] Tenter AM. *Toxoplasma gondii* in animals used for human consumption. *Mem Inst Oswaldo Cruz* 2009; 104(2): 364-9. <http://dx.doi.org/10.1590/S0074-02762009000200033> PMID: 19430665
- [23] Peyron F, L'ollivier C, Mandelbrot L, et al. Maternal and

- congenital toxoplasmosis: Diagnosis and treatment recommendations of a french multidisciplinary working group. *Pathogens* 2019; 8(1): 24.
<http://dx.doi.org/10.3390/pathogens8010024> PMID: 30781652
- [24] Wang ZD, Liu HH, Ma ZX, et al. *Toxoplasma gondii* infection in immunocompromised patients: A systematic review and meta-analysis. *Front Microbiol* 2017; 8: 389.
<http://dx.doi.org/10.3389/fmicb.2017.00389> PMID: 28337191
- [25] Dubey JP, Murata FHA, Cerqueira-Cézar CK, Kwok OCH, Su C, Grigg ME. Recent aspects on epidemiology, clinical disease, and genetic diversity of *Toxoplasma gondii* infections in Australasian marsupials. *Parasit Vectors* 2021; 14(1): 301.
<http://dx.doi.org/10.1186/s13071-021-04793-4> PMID: 34090502
- [26] Melchor SJ, Ewald SE. Disease tolerance in *Toxoplasma* infection. *Front Cell Infect Microbiol* 2019; 9: 185.
<http://dx.doi.org/10.3389/fcimb.2019.00185> PMID: 31245299
- [27] Chaudhry SA, Gad N, Koren G. Toxoplasmosis and pregnancy. *Can Fam Physician* 2014; 60(4): 334-6.
PMID: 24733322
- [28] Asproudis I, Koumpoulis I, Kalogeropoulos C, Sotiropoulos G, Papassava M, Aspiotis M. Case report of a neonate with ocular toxoplasmosis due to congenital infection: Estimation of the percentage of ocular toxoplasmosis in Greece caused by congenital or acquired infection. *Clin Ophthalmol* 2013; 7: 2249-52.
<http://dx.doi.org/10.2147/OPTH.S51740> PMID: 24293989
- [29] Basavaraju A. Toxoplasmosis in HIV infection: An overview. *Trop Parasitol* 2016; 6(2): 129-35.
<http://dx.doi.org/10.4103/2229-5070.190817> PMID: 27722101
- [30] Ferguson DJ. *Toxoplasma gondii*: 1908-2008, homage to Nicolle, Manceaux and Splendore. *Mem Inst Oswaldo Cruz* 2009; 104(2): 133-48.
- [31] Feitosa LCS, Celestino ACTL, Ferreira SB, et al. Serological evidence of *Toxoplasma gondii* occurrence in naturally infected sheep in the Teresina microregion, Piauí, Brazil. *Arq Inst Biol* 2021; 88: e00152020.
<http://dx.doi.org/10.1590/1808-1657000152020>
- [32] Cerutti A, Blanchard N, Besteiro S. The bradyzoite: A key developmental stage for the persistence and pathogenesis of toxoplasmosis. *Pathogens* 2020; 9(3): 234.
<http://dx.doi.org/10.3390/pathogens9030234> PMID: 32245165
- [33] Dard C, Swale C, Brenier-Pinchart MP, et al. A brain cyst load-associated antigen is a *Toxoplasma gondii* biomarker for serodetection of persistent parasites and chronic infection. *BMC Biol* 2021; 19(1): 25.
<http://dx.doi.org/10.1186/s12915-021-00959-9> PMID: 33557824
- [34] Khademvatan S, Abdizadeh R, Rahim F, Hashemitabar M, Tavalla M, Tavalla M. Stray cats gastrointestinal parasites and its association with public health in Ahvaz city, South Western of Iran. *Jundishapur J Microbiol* 2014; 7(7): e11079.
<http://dx.doi.org/10.5812/ijm.11079> PMID: 25485047
- [35] Martorelli Di Genova B, Wilson SK, Dubey JP, Knoll LJ. Intestinal delta-6-desaturase activity determines host range for *Toxoplasma* sexual reproduction. *PLoS Biol* 2019; 17(8): e3000364.
<http://dx.doi.org/10.1371/journal.pbio.3000364> PMID: 31430281
- [36] Ingram WM, Goodrich LM, Robey EA, Eisen MB. Mice infected with low-virulence strains of *Toxoplasma gondii* lose their innate aversion to cat urine, even after extensive parasite clearance. *PLoS One* 2013; 8(9): e75246.
<http://dx.doi.org/10.1371/journal.pone.0075246> PMID: 24058668
- [37] Di Cristina M, Marocco D, Galizi R, Proietti C, Spaccapelo R, Crisanti A. Temporal and spatial distribution of *Toxoplasma gondii* differentiation into Bradyzoites and tissue cyst formation *in vivo*. *Infect Immun* 2008; 76(8): 3491-501.
<http://dx.doi.org/10.1128/IAI.00254-08> PMID: 18505811
- [38] Vidal JE. HIV-related cerebral toxoplasmosis revisited: Current concepts and controversies of an old disease. *J Int Assoc Provid AIDS Care* 2019; 18
<http://dx.doi.org/10.1177/2325958219867315> PMID: 31429353
- [39] Tomasina R, Francia ME. The structural and molecular underpinnings of gametogenesis in *toxoplasma gondii*. *Front Cell Infect Microbiol* 2020; 10: 608291.
<http://dx.doi.org/10.3389/fcimb.2020.608291> PMID: 33365279
- [40] Khelifa AS, Guillen Sanchez C, Lesage KM, et al. TgAP2IX-5 is a key transcriptional regulator of the asexual cell cycle division in *Toxoplasma gondii*. *Nat Commun* 2021; 12(1): 116.
<http://dx.doi.org/10.1038/s41467-020-20216-x> PMID: 33414462
- [41] Hatter JA, Kouche YM, Melchor SJ, et al. *Toxoplasma gondii* infection triggers chronic cachexia and sustained commensal dysbiosis in mice. *PLoS One* 2018; 13(10): e0204895.
<http://dx.doi.org/10.1371/journal.pone.0204895> PMID: 30379866
- [42] Behnke MS, Zhang TP, Dubey JP, Sibley L. *Toxoplasma gondii* merozoite gene expression analysis with comparison to the life cycle discloses a unique expression state during enteric development. *BMC Genomics* 2014; 15(1): 350.
<http://dx.doi.org/10.1186/1471-2164-15-350> PMID: 24885521
- [43] Poulle ML, Forin-Wiart MA, Josse-Dupuis É, Villena I, Aubert D. Detection of *Toxoplasma gondii* DNA by qPCR in the feces of a cat that recently ingested infected prey does not necessarily imply oocyst shedding. *Parasite* 2016; 23: 29.
<http://dx.doi.org/10.1051/parasite/2016029> PMID: 27449050
- [44] Freppel W, Ferguson DJP, Shapiro K, Dubey JP, Puech PH, Dumètre A. Structure, composition, and roles of the *Toxoplasma gondii* oocyst and sporocyst walls. *Cell Surf* 2019; 5: 100016.
<http://dx.doi.org/10.1016/j.tcsv.2018.100016> PMID: 32743133
- [45] Sena F, Cancela S, Bollati-Fogolin M, Pagotto R, Francia ME. Exploring *Toxoplasma gondii*'s Biology within the Intestinal Epithelium: Intestinal-derived models to unravel sexual differentiation. *Front Cell Infect Microbiol* 2023; 13: 1134471.
<http://dx.doi.org/10.3389/fcimb.2023.1134471> PMID: 37313339
- [46] Mévélec MN, Lakhri Z, Dimier-Poisson I. Key limitations and new insights into the *toxoplasma gondii* parasite stage switching for future vaccine development in human, livestock, and cats. *Front Cell Infect Microbiol* 2020; 10: 607198.
<http://dx.doi.org/10.3389/fcimb.2020.607198> PMID: 33324583
- [47] Cirino CCI, Nogueira AP, Amate Neto A, Urbano PC, de Nadai TR. *Toxoplasma gondii* pseudocyst in a transbronchial biopsy: A case report. *J Med Case Reports* 2016; 10(1): 261.
<http://dx.doi.org/10.1186/s13256-016-1039-8> PMID: 27658582
- [48] Nyonda MA, Hammoudi PM, Ye S, et al. *Toxoplasma gondii*GRA60 is an effector protein that modulates host cell autonomous immunity and contributes to virulence. *Cell Microbiol* 2021; 23(2): e13278.
<http://dx.doi.org/10.1111/cmi.13278> PMID: 33040458
- [49] Delgado Betancourt E, Hamid B, Fabian BT, Klotz C, Hartmann S, Seiber F. From entry to early dissemination-*toxoplasma gondii*'s initial encounter with its host. *Front Cell Infect Microbiol* 2019; 9: 46.
<http://dx.doi.org/10.3389/fcimb.2019.00046> PMID: 30891433
- [50] Mayoral J, Di Cristina M, Carruthers VB, Weiss LM. *Toxoplasma gondii*. *Methods Mol Biol* 2020; 2071: 269-82.
http://dx.doi.org/10.1007/978-1-4939-9857-9_15 PMID: 31758458
- [51] Almeria S, Dubey JP. Foodborne transmission of *Toxoplasma gondii* infection in the last decade. An overview. *Res Vet Sci* 2021; 135: 371-85.
<http://dx.doi.org/10.1016/j.rvsc.2020.10.019> PMID: 33148402
- [52] Jones EJ, Korcsmaros T, Carding SR. Mechanisms and pathways of *Toxoplasma gondii* transepithelial migration. *Tissue Barriers* 2017; 5(1): e1273865.
<http://dx.doi.org/10.1080/21688370.2016.1273865> PMID: 28452683
- [53] Egarter S, Andenmatten N, Jackson AJ, et al. The toxoplasma Acto-MyoA motor complex is important but not essential for gliding motility and host cell invasion. *PLoS One* 2014; 9(3): e91819.
<http://dx.doi.org/10.1371/journal.pone.0091819> PMID: 24632839
- [54] Leung JM, Rould MA, Konradt C, Hunter CA, Ward GE. Disruption of TgPHIL1 alters specific parameters of *Toxoplasma gondii* motility measured in a quantitative, three-dimensional live motility assay. *PLoS One* 2014; 9(1): e85763.

- <http://dx.doi.org/10.1371/journal.pone.0085763> PMID: 24489670
- [55] Munera Lopez J, Tenggana IF, Liu J, *et al.* An apical protein, Pcr2, is required for persistent movement by the human parasite *Toxoplasma gondii*. *PLoS Pathog* 2022; 18(8): e1010776. <http://dx.doi.org/10.1371/journal.ppat.1010776> PMID: 35994509
- [56] Zhu J, Wang Y, Cao Y, Shen J, Yu L. Diverse roles of TgMIC1/4/6 in the *toxoplasma* infection. *Front Microbiol* 2021; 12: 666506. <http://dx.doi.org/10.3389/fmicb.2021.666506> PMID: 34220751
- [57] Kato K. How does *Toxoplasma gondii* invade host cells? *J Vet Med Sci* 2018; 80(11): 1702-6. <http://dx.doi.org/10.1292/jvms.18-0344> PMID: 30282883
- [58] Augusto L, Wek RC, Sullivan WJ Jr. Host sensing and signal transduction during *Toxoplasma* stage conversion. *Mol Microbiol* 2021; 115(5): 839-48. <http://dx.doi.org/10.1111/mmi.14634> PMID: 33118234
- [59] Blader IJ, Coleman BI, Chen CT, Gubbels MJ. Lytic Cycle of *Toxoplasma gondii* : 15 Years Later. *Annu Rev Microbiol* 2015; 69(1): 463-85. <http://dx.doi.org/10.1146/annurev-micro-091014-104100> PMID: 26332089
- [60] Portes J, Barrias E, Travassos R, Attias M, de Souza W. *Toxoplasma gondii* mechanisms of entry into host cells. *Front Cell Infect Microbiol* 2020; 10: 294. <http://dx.doi.org/10.3389/fcimb.2020.00294> PMID: 32714877
- [61] Blader IJ, Saeij JP. Communication between *Toxoplasma gondii* and its host: Impact on parasite growth, development, immune evasion, and virulence. *Acta Pathol Microbiol Scand Suppl* 2009; 117(5-6): 458-76. <http://dx.doi.org/10.1111/j.1600-0463.2009.02453.x> PMID: 19400868
- [62] Macêdo AG Jr, Cunha JP Jr, Cardoso THS, *et al.* SAG2A protein from *Toxoplasma gondii* interacts with both innate and adaptive immune compartments of infected hosts. *Parasit Vectors* 2013; 6(1): 163. <http://dx.doi.org/10.1186/1756-3305-6-163> PMID: 23735002
- [63] Sardinha-Silva A, Mendonça-Natividade FC, Pinzan CF, *et al.* The lectin-specific activity of *Toxoplasma gondii* microneme proteins 1 and 4 binds Toll-like receptor 2 and 4 N-glycans to regulate innate immune priming. *PLoS Pathog* 2019; 15(6): e1007871. <http://dx.doi.org/10.1371/journal.ppat.1007871> PMID: 31226171
- [64] Dupont CD, Christian DA, Hunter CA. Immune response and immunopathology during toxoplasmosis. *Semin Immunopathol* 2012; 34(6): 793-813. <http://dx.doi.org/10.1007/s00281-012-0339-3> PMID: 22955326
- [65] Arranz-Solís D, Mukhopadhyay D, Saeij JJP. *Toxoplasma* effectors that affect pregnancy outcome. *Trends Parasitol* 2021; 37(4): 283-95. <http://dx.doi.org/10.1016/j.pt.2020.10.013> PMID: 33234405
- [66] Rahman M, Devriendt B, Jennes M, *et al.* Early kinetics of intestinal infection and immune responses to two *toxoplasma gondii* strains in pigs. *Front Cell Infect Microbiol* 2020; 10: 161. <http://dx.doi.org/10.3389/fcimb.2020.00161> PMID: 32373554
- [67] Furtado JM, Bharadwaj AS, Chipps TJ, Pan Y, Ashander LM, Smith JR. *Toxoplasma gondii* tachyzoites cross retinal endothelium assisted by intercellular adhesion molecule-1 *in vitro*. *Immunol Cell Biol* 2012; 90(9): 912-5. <http://dx.doi.org/10.1038/icb.2012.21> PMID: 22525368
- [68] Hunter CA, Sibley LD. Modulation of innate immunity by *Toxoplasma gondii* virulence effectors. *Nat Rev Microbiol* 2012; 10(11): 766-78. <http://dx.doi.org/10.1038/nrmicro2858> PMID: 23070557
- [69] Sullivan WJ Jr, Jeffers V. Mechanisms of *Toxoplasma gondii* persistence and latency. *FEMS Microbiol Rev* 2012; 36(3): 717-33. <http://dx.doi.org/10.1111/j.1574-6976.2011.00305.x> PMID: 22091606
- [70] Khan IA, Ouellette C, Chen K, Moretto M. *Toxoplasma*: Immunity and pathogenesis. *Curr Clin Microbiol Rep* 2019; 6(1): 44-50. <http://dx.doi.org/10.1007/s40588-019-0114-5> PMID: 31179204
- [71] Wohlfert EA, Blader IJ, Wilson EH. Brains and brawn: *Toxoplasma* infections of the central nervous system and skeletal muscle. *Trends Parasitol* 2017; 33(7): 519-31. <http://dx.doi.org/10.1016/j.pt.2017.04.001> PMID: 28483381
- [72] Lopes C, Brandão R, Lopes AF, *et al.* Prevalence of antibodies to *toxoplasma gondii* in different wild bird species admitted to rehabilitation centres in Portugal. *Pathogens* 2021; 10(9): 1144. <http://dx.doi.org/10.3390/pathogens10091144> PMID: 34578176
- [73] Giannoulis C, Zournatzi B, Giomisi A, Diza E, Tzafettas I. *Toxoplasmosis* during pregnancy: A case report and review of the literature. *Hippokratia* 2008; 12(3): 139-43. PMID: 18923664
- [74] Motoi S, Navolan D, Malita D, *et al.* A decreasing trend in *toxoplasma gondii* seroprevalence among pregnant women in Romania-results of a large scale study. *Exp Ther Med* 2020; 20(4): 3536-40. <http://dx.doi.org/10.3892/etm.2020.9012> PMID: 32905270
- [75] Aguirre AA, Longcore T, Barbieri M, *et al.* The one health approach to toxoplasmosis: Epidemiology, control, and prevention strategies. *EcoHealth* 2019; 16(2): 378-90. <http://dx.doi.org/10.1007/s10393-019-01405-7> PMID: 30945159
- [76] Schares G, Ziller M, Herrmann DC, Globokar MV, Pantchev N, Conraths FJ. Seasonality in the proportions of domestic cats shedding *Toxoplasma gondii* or *Hammondia hammondi* oocysts is associated with climatic factors. *Int J Parasitol* 2016; 46(4): 263-73. <http://dx.doi.org/10.1016/j.ijpara.2015.12.006> PMID: 26820303
- [77] Friesema IHM, Hofhuis A, Hoek-van Deursen D, *et al.* Risk factors for acute toxoplasmosis in the Netherlands. *Epidemiol Infect* 2023; 151: e95. <http://dx.doi.org/10.1017/S0950268823000808> PMID: 37222136
- [78] Cong W, Li MY, Zou Y, *et al.* Prevalence, genotypes and risk factors for *Toxoplasma gondii* contamination in marine bivalve shellfish in offshore waters in eastern China. *Ecotoxicol Environ Saf* 2021; 213: 112048. <http://dx.doi.org/10.1016/j.ecoenv.2021.112048> PMID: 33610941
- [79] Huang J, Zheng J, Liu B, *et al.* The association between *Toxoplasma* infection and mortality: The NHANES epidemiologic follow-up study. *Parasit Vectors* 2022; 15(1): 284. <http://dx.doi.org/10.1186/s13071-022-05398-1> PMID: 35933421
- [80] Šušak B, Martinović K, Jakovac S, Arapović J. Seroprevalence of *Toxoplasma gondii* among general population in Bosnia and Herzegovina: 10-Years single center experience. *Clin Epidemiol Glob Health* 2023; 22: 101336. <http://dx.doi.org/10.1016/j.cegh.2023.101336>
- [81] Jones JL, Dubey JP. Waterborne toxoplasmosis - Recent developments. *Exp Parasitol* 2010; 124(1): 10-25. <http://dx.doi.org/10.1016/j.exppara.2009.03.013> PMID: 19324041
- [82] Mareze M, Benitez AN, Brandão APD, *et al.* Socioeconomic vulnerability associated to *Toxoplasma gondii* exposure in southern Brazil. *PLoS One* 2019; 14(2): e0212375. <http://dx.doi.org/10.1371/journal.pone.0212375> PMID: 30763391
- [83] Bahia-Oliveira LMG, Jones JL, Azevedo-Silva J, Alves CCF, Oréface F, Addiss DG. Highly endemic, waterborne toxoplasmosis in north Rio de Janeiro state, Brazil. *Emerg Infect Dis* 2003; 9(1): 55-62. <http://dx.doi.org/10.3201/eid0901.020160> PMID: 12533282
- [84] Polanunu NFA, Wahyuni S, Hamid F. Seroprevalence and associated risk factors of *Toxoplasma gondii* infection among pregnant mother in Makassar, Indonesia. *PLoS One* 2021; 16(6): e0245572. <http://dx.doi.org/10.1371/journal.pone.0245572> PMID: 34086692
- [85] Begeman IJ, Lykins J, Zhou Y, *et al.* Point-of-care testing for *Toxoplasma gondii* IgG/IgM using *Toxoplasma* ICT IgG-IgM test with sera from the United States and implications for developing countries. *PLoS Negl Trop Dis* 2017; 11(6): e0005670. <http://dx.doi.org/10.1371/journal.pntd.0005670> PMID: 28650970
- [86] Hotez PJ. Neglected parasitic infections and poverty in the United States. *PLoS Negl Trop Dis* 2014; 8(9): e3012. <http://dx.doi.org/10.1371/journal.pntd.0003012> PMID: 25188455
- [87] Zhu S, VanWormer E, Martínez-López B, *et al.* Quantitative risk assessment of oocyst versus bradyzoite foodborne transmission of *toxoplasma gondii* in Brazil. *Pathogens* 2023; 12(7): 870.

- <http://dx.doi.org/10.3390/pathogens12070870> PMID: 37513717
- [88] Wallon M, Peyron F. Congenital toxoplasmosis: A plea for a neglected disease. *Pathogens* 2018; 7(1): 25. <http://dx.doi.org/10.3390/pathogens7010025> PMID: 29473896
- [89] Milne GC, Webster JP, Walker M. Is the incidence of congenital toxoplasmosis declining? *Trends Parasitol* 2023; 39(1): 26-37. <http://dx.doi.org/10.1016/j.pt.2022.10.003> PMID: 36400672
- [90] Dini FM, Morselli S, Marangoni A, et al. Spread of *Toxoplasma gondii* among animals and humans in Northern Italy: A retrospective analysis in a One-Health framework. *Food Water Parasitol* 2023; 32: e00197. <http://dx.doi.org/10.1016/j.fawpar.2023.e00197> PMID: 37333686
- [91] Saad NM, Hussein AAA, Ewida RM. Occurrence of *Toxoplasma gondii* in raw goat, sheep, and camel milk in Upper Egypt. *Vet World* 2018; 11(9): 1262-5. <http://dx.doi.org/10.14202/vetworld.2018.1262-1265> PMID: 30410231
- [92] Hill DE, Chirukandoth S, Dubey JP. Biology and epidemiology of *Toxoplasma gondii* in man and animals. *Anim Health Res Rev* 2005; 6(1): 41-61. <http://dx.doi.org/10.1079/AHR2005100> PMID: 16164008
- [93] Dawson AC, Ashander LM, Appukuttan B, et al. Lamb as a potential source of *Toxoplasma gondii* infection for Australians. *Aust N Z J Public Health* 2020; 44(1): 49-52. <http://dx.doi.org/10.1111/1753-6405.12955> PMID: 31825558
- [94] Snyder LM, Denkers EY. From initiators to effectors: Roadmap through the intestine during encounter of *toxoplasma gondii* with the mucosal immune system. *Front Cell Infect Microbiol* 2021; 10: 614701. <http://dx.doi.org/10.3389/fcimb.2020.614701> PMID: 33505924
- [95] Salant H, Hamburger J, Spira DT. A comparative analysis of coprologic diagnostic methods for detection of *Toxoplasma gondii* in cats. *Am J Trop Med Hyg* 2010; 82(5): 865-70. <http://dx.doi.org/10.4269/ajtmh.2010.09-0635> PMID: 20439968
- [96] Kurth K, Jiang T, Muller L, Su C, Gerhold RW. *Toxoplasma gondii* contamination at an animal agriculture facility: Environmental, agricultural animal, and wildlife contamination indicator evaluation. *Int J Parasitol Parasites Wildl* 2021; 16: 191-8. <http://dx.doi.org/10.1016/j.ijppaw.2021.09.009> PMID: 34667717
- [97] Hussain M, Stitt V, Szabo E, Nelan B. *Toxoplasma gondii* in the food supply. *Pathogens* 2017; 6(2): 21. <http://dx.doi.org/10.3390/pathogens6020021> PMID: 28587147
- [98] Ebrahimi M, Ahmadi A, Yaghfoori S, Rassouli M, Azizzadeh M. Evaluating the prior knowledge of toxoplasmosis among students of Ferdowsi University of Mashhad. *Med J Islam Repub Iran* 2015; 29: 163. PMID: 26000258
- [99] Lilly EL, Wortham CD. High prevalence of *Toxoplasma gondii* oocyst shedding in stray and pet cats (*Felis catus*) in Virginia, United States. *Parasit Vectors* 2013; 6(1): 266. <http://dx.doi.org/10.1186/1756-3305-6-266> PMID: 24330950
- [100] Gaulin C, Ramsay D, Thivierge K, et al. Acute toxoplasmosis among canadian deer hunters associated with consumption of undercooked deer meat hunted in the United States. *Emerg Infect Dis* 2020; 26(2): 199-205. <http://dx.doi.org/10.3201/eid2602.191218> PMID: 31961291
- [101] Zulpo DL, Sammi AS, dos Santos JR, et al. *Toxoplasma gondii*: A study of oocyst re-shedding in domestic cats. *Vet Parasitol* 2018; 249: 17-20. <http://dx.doi.org/10.1016/j.vetpar.2017.10.021> PMID: 29279081
- [102] Lindsay DS, Dubey JP. Long-term survival of *Toxoplasma gondii* sporulated oocysts in seawater. *J Parasitol* 2009; 95(4): 1019-20. <http://dx.doi.org/10.1645/GE-1919.1> PMID: 20050010
- [103] Lueder CGK, Rahman T. Impact of the host on *Toxoplasma* stage differentiation. *Microb Cell* 2017; 4(7): 203-11. <http://dx.doi.org/10.15698/mic2017.07.579> PMID: 28706936
- [104] Massie GN, Ware MW, Villegas EN, Black MW. Uptake and transmission of *Toxoplasma gondii* oocysts by migratory, filter-feeding fish. *Vet Parasitol* 2010; 169(3-4): 296-303. <http://dx.doi.org/10.1016/j.vetpar.2010.01.002> PMID: 20097009
- [105] Khan K, Khan W. Congenital toxoplasmosis: An overview of the neurological and ocular manifestations. *Parasitol Int* 2018; 67(6): 715-21. <http://dx.doi.org/10.1016/j.parint.2018.07.004> PMID: 30041005
- [106] McAuley JB. Congenital toxoplasmosis. *J Pediatric Infect Dis Soc* 2014; 3(Suppl 1): S30-5. <http://dx.doi.org/10.1093/jpids/piu077> PMID: 25232475
- [107] Briciu V, Ionică AM, Flonta M, et al. Toxoplasmosis screening during pregnancy in a romanian infectious diseases tertiary center: Results of a 15 years follow-up program. *Microorganisms* 2023; 11(9): 2189. <http://dx.doi.org/10.3390/microorganisms11092189> PMID: 37764033
- [108] Fallahi S, Rostami A, Nourollahpour Shiadeh M, Behniafar H, Paktinat S. An updated literature review on maternal-fetal and reproductive disorders of *Toxoplasma gondii* infection. *J Gynecol Obstet Hum Reprod* 2018; 47(3): 133-40. <http://dx.doi.org/10.1016/j.jogoh.2017.12.003> PMID: 29229361
- [109] Bollani L, Auriti C, Achille C, et al. Congenital toxoplasmosis: The state of the art. *Front Pediatr* 2022; 10: 894573. <http://dx.doi.org/10.3389/fped.2022.894573> PMID: 35874584
- [110] Galvan-Ramírez ML, Troyo-Sanroman R, Roman S, Bernal-Redondo R, Vázquez Castellanos JL. Prevalence of toxoplasma infection in Mexican newborns and children: A systematic review from 1954 to 2009. *ISRN Pediatr* 2012; 2012: 1-5. <http://dx.doi.org/10.5402/2012/501216> PMID: 23050161
- [111] Faral-Tello P, Pagotto R, Bollati-Fogolin M, Francia ME. Modeling the human placental barrier to understand *Toxoplasma gondii*'s vertical transmission. *Front Cell Infect Microbiol* 2023; 13: 1130901. <http://dx.doi.org/10.3389/fcimb.2023.1130901> PMID: 36968102
- [112] Vargas-Villavicencio JA, Cedillo-Peláez C, Aguilar-Orozco MI, Rico-Torres CP, Farfan-Morales JE, Correa D. Vertical transmission and pathological findings in the mother, the placenta and the offspring, during first and last thirds of gestation in a mouse model of congenital toxoplasmosis. *Parasitol Int* 2022; 91: 102640. <http://dx.doi.org/10.1016/j.parint.2022.102640> PMID: 35933034
- [113] Ferreira SCM, Torelli F, Klein S, et al. Evidence of high exposure to *Toxoplasma gondii* in free-ranging and captive African carnivores. *Int J Parasitol Parasites Wildl* 2019; 8: 111-7. <http://dx.doi.org/10.1016/j.ijppaw.2018.12.007> PMID: 30740303
- [114] Marino AMF, Giunta RP, Salvaggio A, et al. *Toxoplasma gondii* in edible fishes captured in the Mediterranean basin. *Zoonoses Public Health* 2019; 66(7): 826-34. <http://dx.doi.org/10.1111/zph.12630> PMID: 31278858
- [115] Abdul Basit K, Nasir S, Vohra E, Shazlee MK. Toxoplasmosis in an immunocompetent patient. *Pak J Med Sci* 2018; 34(6): 1579-81. <http://dx.doi.org/10.12669/pjms.346.15016> PMID: 30559827
- [116] Kalogeropoulos D, Sakkas H, Mohammed B, et al. Ocular toxoplasmosis: A review of the current diagnostic and therapeutic approaches. *Int Ophthalmol* 2022; 42(1): 295-321. <http://dx.doi.org/10.1007/s10792-021-01994-9> PMID: 34370174
- [117] Park YH, Nam HW. Clinical features and treatment of ocular toxoplasmosis. *Korean J Parasitol* 2013; 51(4): 393-9. <http://dx.doi.org/10.3347/kjp.2013.51.4.393> PMID: 24039281
- [118] Furtado J, Smith J, Belfort R Jr, Gattey D, Winthrop K. Toxoplasmosis: A global threat. *J Glob Infect Dis* 2011; 3(3): 281-4. <http://dx.doi.org/10.4103/0974-777X.83536> PMID: 21887062
- [119] Aleixo ALQC, Curi ALL, Benchimol EI, Amendoeira MRR. Toxoplasmic retinochoroiditis: Clinical characteristics and visual outcome in a prospective study. *PLoS Negl Trop Dis* 2016; 10(5): e0004685. <http://dx.doi.org/10.1371/journal.pntd.0004685> PMID: 27136081
- [120] Greigert V, Bittich-Fahmi F, Pfaff AW. Pathophysiology of ocular toxoplasmosis: Facts and open questions. *PLoS Negl Trop Dis* 2020; 14(12): e0008905. <http://dx.doi.org/10.1371/journal.pntd.0008905> PMID: 33382688
- [121] Goh EJH, Putera I, La Distia Nora R, et al. Ocular toxoplasmosis.

- Ocul Immunol Inflamm 2023; 31(7): 1342-61.
<http://dx.doi.org/10.1080/09273948.2022.2117705> PMID: 36095008
- [122] Lee SB, Lee TG. Toxoplasmic encephalitis in patient with acquired immunodeficiency syndrome. *Brain Tumor Res Treat* 2017; 5(1): 34-6.
<http://dx.doi.org/10.14791/btrt.2017.5.1.34> PMID: 28516077
- [123] Liang B, Yang SY, Chen JM, *et al.* Diagnostic value of real-time PCR of brain mass lesion in HIV-associated toxoplasmic encephalitis: A case series. *Parasit Vectors* 2020; 13(1): 564.
<http://dx.doi.org/10.1186/s13071-020-04443-1> PMID: 33172484
- [124] Soleymani E, Babamahmoodi F, Davoodi L, Marofi A, Nooshirvanpour P. Toxoplasmic encephalitis in an AIDS patient with normal CD4 count: A case report. *Iran J Parasitol* 2018; 13(2): 317-22.
 PMID: 30069217
- [125] Ramachandran R, Radhan P, Anand R, Subramanian I, Santosham R, Sai V. CNS toxoplasmosis in an immunocompetent individual. *Radiol Case Rep* 2014; 9(1): 908.
<http://dx.doi.org/10.2484/rcr.v9i1.908> PMID: 27141248
- [126] Li J, Zhao J, Yang X, *et al.* One severe case of congenital toxoplasmosis in China with good response to azithromycin. *BMC Infect Dis* 2021; 21(1): 920.
<http://dx.doi.org/10.1186/s12879-021-06619-1> PMID: 34488656
- [127] Kortbeek LM, Hoffhuis A, Nijhuis CDM, Havelaar AH. Congenital toxoplasmosis and DALYs in the Netherlands. *Mem Inst Oswaldo Cruz* 2009; 104(2): 370-3.
<http://dx.doi.org/10.1590/S0074-02762009000200034> PMID: 19430666
- [128] Bintsis T. Foodborne pathogens. *AIMS Microbiol* 2017; 3(3): 529-63.
<http://dx.doi.org/10.3934/microbiol.2017.3.529> PMID: 31294175
- [129] Saade C, Najem E, Asmar K, Salman R, El Achkar B, Naffaa L. Intracranial calcifications on CT: An updated review. *J Radiol Case Rep* 2019; 13(8): 1-18.
<http://dx.doi.org/10.3941/jrcr.v13i8.3633> PMID: 31558966
- [130] Flegr J. Neurological and neuropsychiatric consequences of chronic toxoplasma infection. *Curr Clin Microbiol Rep* 2015; 2(4): 163-72.
<http://dx.doi.org/10.1007/s40588-015-0024-0>
- [131] Garweg JG, Kieffer F, Mandelbrot L, Peyron F, Wallon M. Long-term outcomes in children with congenital toxoplasmosis-A systematic review. *Pathogens* 2022; 11(10): 1187.
<http://dx.doi.org/10.3390/pathogens11101187> PMID: 36297244
- [132] Tan HK, Schmidt D, Stanford M, *et al.* Risk of visual impairment in children with congenital toxoplasmic retinochoroiditis. *Am J Ophthalmol* 2007; 144(5): 648-653.e2.
<http://dx.doi.org/10.1016/j.ajo.2007.07.013> PMID: 17854757
- [133] Pomares C, Montoya JG. Laboratory diagnosis of congenital toxoplasmosis. *J Clin Microbiol* 2016; 54(10): 2448-54.
<http://dx.doi.org/10.1128/JCM.00487-16> PMID: 27147724
- [134] Al-Adhroey AH, Mehrass AAKO, Al-Shammakh AA, Ali AD, Akabat MYM, Al-Mekhlafi HM. Prevalence and predictors of *Toxoplasma gondii* infection in pregnant women from Dhamar, Yemen. *BMC Infect Dis* 2019; 19(1): 1089.
<http://dx.doi.org/10.1186/s12879-019-4718-4> PMID: 31888517
- [135] Paul M. Serological screening of newborns for *toxoplasma gondii*-specific IgA and IgM antibodies in peripheral blood collected on filter-papers. *EJIFCC* 2007; 18(3): 91-114.
 PMID: 29606933
- [136] Villard O, Cimon B, L'Ollivier C, *et al.* Serological diagnosis of *Toxoplasma gondii* infection. *Diagn Microbiol Infect Dis* 2016; 84(1): 22-33.
<http://dx.doi.org/10.1016/j.diagmicrobio.2015.09.009> PMID: 26458281
- [137] Calderaro A, Piccolo G, Peruzzi S, Gorrini C, Chezzi C, Dettori G. Evaluation of *Toxoplasma gondii* immunoglobulin G (IgG) and IgM assays incorporating the newVidia analyzer system. *Clin Vaccine Immunol* 2008; 15(7): 1076-9.
<http://dx.doi.org/10.1128/00025-08> PMID: 18480234
- [138] Liu Q, Wang ZD, Huang SY, Zhu XQ. Diagnosis of toxoplasmosis and typing of *Toxoplasma gondii*. *Parasit Vectors* 2015; 8(1): 292.
<http://dx.doi.org/10.1186/s13071-015-0902-6> PMID: 26017718
- [139] Khan AH, Noordin R. Serological and molecular rapid diagnostic tests for *Toxoplasma* infection in humans and animals. *Eur J Clin Microbiol Infect Dis* 2020; 39(1): 19-30.
<http://dx.doi.org/10.1007/s10096-019-03680-2> PMID: 31428897
- [140] Sharifi K, Hosseini Farash BR, Tara F, Khaledi A, Sharifi K, Shamsian SAA. Diagnosis of acute toxoplasmosis by IgG and IgM antibodies and IgG avidity in pregnant women from mashhad, Eastern Iran. *Iran J Parasitol* 2019; 14(4): 639-45.
<http://dx.doi.org/10.18502/ijpa.v14i4.2107> PMID: 32099567
- [141] Teimouri A, Mohtasebi S, Kazemirad E, Keshavarz H. Role of *Toxoplasma gondii* IgG avidity testing in discriminating between acute and chronic toxoplasmosis in pregnancy. *J Clin Microbiol* 2020; 58(9): e00505-20.
<http://dx.doi.org/10.1128/JCM.00505-20> PMID: 32321784
- [142] Nasir IA, Shehu MS, Adekola HA. Anti-*Toxoplasma gondii* IgG avidity testing is necessary for diagnosis of acute toxoplasmosis. *J Taibah Univ Med Sci* 2017; 12(1): 87-8.
<http://dx.doi.org/10.1016/j.jtumed.2016.11.004> PMID: 31435220
- [143] Singh J, Graniello C, Ni Y, *et al.* *Toxoplasma* IgG and IgA, but not IgM, antibody titers increase in sera of immunocompetent mice in association with proliferation of tachyzoites in the brain during the chronic stage of infection. *Microbes Infect* 2010; 12(14-15): 1252-7.
<http://dx.doi.org/10.1016/j.micinf.2010.07.016> PMID: 20708090
- [144] Montoya JG, Remington JS. Management of *Toxoplasma gondii* infection during pregnancy. *Clin Infect Dis* 2008; 47(4): 554-66.
<http://dx.doi.org/10.1086/590149> PMID: 18624630
- [145] Döşkaya M, Caner A, Can H, *et al.* Diagnostic value of a Rec-ELISA using *Toxoplasma gondii* recombinant SporoSAG, BAG1, and GRA1 proteins in murine models infected orally with tissue cysts and oocysts. *PLoS One* 2014; 9(9): e108329.
<http://dx.doi.org/10.1371/journal.pone.0108329> PMID: 25268351
- [146] Kodym P, Kurzová Z, Berenová D, Malý M. Detection of persistent low IgG avidity-an interpretative problem in the diagnosis of acute toxoplasmosis. *PLoS One* 2023; 18(4): e0284499.
<http://dx.doi.org/10.1371/journal.pone.0284499> PMID: 37053239
- [147] Landry ML. Immunoglobulin M for acute infection: True or false? *Clin Vaccine Immunol* 2016; 23(7): 540-5.
<http://dx.doi.org/10.1128/00021-16> PMID: 27193039
- [148] Guegan H, Stajner T, Bobic B, *et al.* Maternal anti-*toxoplasma* treatment during pregnancy is associated with reduced sensitivity of diagnostic tests for congenital infection in the neonate. *J Clin Microbiol* 2021; 59(2): e01368-20.
<http://dx.doi.org/10.1128/JCM.01368-20> PMID: 33208476
- [149] Findal G, Helbig A, Haugen G, Jennum PA, Stray-Pedersen B. Management of suspected primary *Toxoplasma gondii* infection in pregnant women in Norway: Twenty years of experience of amniocentesis in a low-prevalence population. *BMC Preg Childbirth* 2017; 17(1): 127.
<http://dx.doi.org/10.1186/s12884-017-1300-1> PMID: 28441952
- [150] de Oliveira Azevedo CT, do Brasil PEAA, Guida L, Lopes Moreira ME. Performance of polymerase chain reaction analysis of the amniotic fluid of pregnant women for diagnosis of congenital toxoplasmosis: A systematic review and meta-analysis. *PLoS One* 2016; 11(4): e0149938.
<http://dx.doi.org/10.1371/journal.pone.0149938> PMID: 27055272
- [151] Remington JS, Thulliez P, Montoya JG. Recent developments for diagnosis of toxoplasmosis. *J Clin Microbiol* 2004; 42(3): 941-5.
<http://dx.doi.org/10.1128/JCM.42.3.941-945.2004> PMID: 15004036
- [152] Lazarte-Rantes C, Rodríguez-Anccasi R, Rivas-Campos C, Silva E. Congenital toxoplasmosis: Findings in fetal MRI. *Cureus* 2021; 13(8): e16894.
<http://dx.doi.org/10.7759/cureus.16894> PMID: 34513467
- [153] McLeod R, Kieffer F, Sautter M, Hosten T, Pelloux H. Why prevent, diagnose and treat congenital toxoplasmosis? *Mem Inst Oswaldo Cruz* 2009; 104(2): 320-44.

- <http://dx.doi.org/10.1590/S0074-02762009000200029> PMID: 19430661
- [154] Di Mario S, Basevi V, Gagliotti C, et al. Prenatal education for congenital toxoplasmosis. *Cochrane Libr* 2015; 2015(10): CD006171. <http://dx.doi.org/10.1002/14651858.CD006171.pub4> PMID: 26493047
- [155] Retmanasari A, Widartono BS, Wijayanti MA, Artama WT. Prevalence and risk factors for toxoplasmosis in middle java, Indonesia. *EcoHealth* 2017; 14(1): 162-70. <http://dx.doi.org/10.1007/s10393-016-1198-5> PMID: 27830388
- [156] Iddawela D, Vithana SMP, Ratnayake C. Seroprevalence of toxoplasmosis and risk factors of *Toxoplasma gondii* infection among pregnant women in Sri Lanka: A cross sectional study. *BMC Public Health* 2017; 17(1): 930. <http://dx.doi.org/10.1186/s12889-017-4941-0> PMID: 29202747
- [157] Wesolowski R, Pawłowska M, Smogula M, Szweczyk-Golec K. Advances and challenges in diagnostics of toxoplasmosis in HIV-Infected patients. *Pathogens* 2023; 12(1): 110. <http://dx.doi.org/10.3390/pathogens12010110> PMID: 36678458
- [158] Khurana S, Batra N. Toxoplasmosis in organ transplant recipients: Evaluation, implication, and prevention. *Trop Parasitol* 2016; 6(2): 123-8. <http://dx.doi.org/10.4103/2229-5070.190814> PMID: 27722100
- [159] Elsheikha HM, Marra CM, Zhu XQ. Epidemiology, pathophysiology, diagnosis, and management of cerebral toxoplasmosis. *Clin Microbiol Rev* 2020; 34(1): e00115-19. <http://dx.doi.org/10.1128/CMR.00115-19> PMID: 33239310
- [160] Tenter AM, Heckerroth AR, Weiss LM. *Toxoplasma gondii*: From animals to humans. *Int J Parasitol* 2000; 30(12-13): 1217-58. [http://dx.doi.org/10.1016/S0020-7519\(00\)00124-7](http://dx.doi.org/10.1016/S0020-7519(00)00124-7) PMID: 11113252
- [161] Lampejo T. *Toxoplasma gondii* infection in HIV-infected pregnant women: epidemiology and risks of mother-to-child transmission. *Pan Afr Med J* 2022; 42: 275. <http://dx.doi.org/10.11604/2Fpamj.2022.42.275.33160> PMID: 36405653
- [162] Deganich M, Boudreaux C, Benmerzouga I. Toxoplasmosis infection during pregnancy. *Trop Med Infect Dis* 2022; 8(1): 3. <http://dx.doi.org/10.3390/tropicalmed8010003> PMID: 36668910
- [163] Selim A, Marawan MA, Abdelhady A, Wakid MH. Seroprevalence and potential risk factors of *toxoplasma gondii* in dromedary camels. *Agriculture* 2023; 13(1): 129. <http://dx.doi.org/10.3390/agriculture13010129>
- [164] Clune T, Lockwood A, Hancock S, et al. *Toxoplasma gondii* is not an important contributor to poor reproductive performance of primiparous ewes from southern Australia: A prospective cohort study. *BMC Vet Res* 2022; 18(1): 109. <http://dx.doi.org/10.1186/s12917-022-03211-w> PMID: 35305646
- [165] Rajapakse S, Chrisan Shivanthan M, Samaranyake N, Rodrigo C, Deepika Fernando S. Antibiotics for human toxoplasmosis: A systematic review of randomized trials. *Pathog Glob Health* 2013; 107(4): 162-9. <http://dx.doi.org/10.1179/2047773213Y.0000000094> PMID: 23816507
- [166] Manuel L, Santos-Gomes G, Noormahomed EV. Human toxoplasmosis in Mozambique: Gaps in knowledge and research opportunities. *Parasit Vectors* 2020; 13(1): 571. <http://dx.doi.org/10.1186/s13071-020-04441-3> PMID: 33176884
- [167] Hopper AT, Brockman A, Wise A, et al. Discovery of selective *toxoplasma gondii* dihydrofolate reductase inhibitors for the treatment of toxoplasmosis. *J Med Chem* 2019; 62(3): 1562-76. <http://dx.doi.org/10.1021/acs.jmedchem.8b01754> PMID: 30624926
- [168] Ben-Harari RR, Goodwin E, Casoy J. Adverse event profile of pyrimethamine-based therapy in toxoplasmosis: A systematic review. *Drugs R D* 2017; 17(4): 523-44. <http://dx.doi.org/10.1007/s40268-017-0206-8> PMID: 28879584
- [169] Dunay IR, Gajurel K, Dhakal R, Liesenfeld O, Montoya JG. Treatment of toxoplasmosis: Historical perspective, animal models, and current clinical practice. *Clin Microbiol Rev* 2018; 31(4): e00057-17. <http://dx.doi.org/10.1128/CMR.00057-17> PMID: 30209035
- [170] Konstantinovic N, Guegan H, Stājner T, Belaz S, Robert-Gangneux F. Treatment of toxoplasmosis: Current options and future perspectives. *Food Waterb Parasitol* 2019; 15: e00036. <http://dx.doi.org/10.1016/j.fawpar.2019.e00036> PMID: 32095610
- [171] Castaño BL, Silva AA, Hernandez-Velasco LL, et al. Sulfadiazine plus pyrimethamine therapy reversed multiple behavioral and neurocognitive changes in long-term chronic toxoplasmosis by reducing brain cyst load and inflammation-related alterations. *Front Immunol* 2022; 13: 822567. <http://dx.doi.org/10.3389/fimmu.2022.822567> PMID: 35572567
- [172] Madi D, Achappa B, Rao S, Ramapuram JT, Mahalingam S. Successful treatment of cerebral toxoplasmosis with clindamycin: A case report. *Oman Med J* 2012; 27(5): 411-2. <http://dx.doi.org/10.5001/omj.2012.100> PMID: 23074553
- [173] Barros M, Teixeira D, Vilanova M, Correia A, Teixeira N, Borges M. Vaccines in congenital toxoplasmosis: Advances and perspectives. *Front Immunol* 2021; 11: 621997. <http://dx.doi.org/10.3389/fimmu.2020.621997> PMID: 33658997
- [174] Ferra B, Holec-Gąsior L, Gatkowska J, Dziadek B, Dzitko K. *Toxoplasma gondii* recombinant antigen AMA1: Diagnostic utility of protein fragments for the detection of IgG and IgM antibodies. *Pathogens* 2020; 9(1): 43. <http://dx.doi.org/10.3390/pathogens9010043> PMID: 31948063
- [175] Alday H, Doggett J. Drugs in development for toxoplasmosis: Advances, challenges, and current status. *Drug Des Devel Ther* 2017; 11: 273-93. <http://dx.doi.org/10.2147/DDDT.S60973> PMID: 28182168
- [176] Damar Çakırca T, Can İN, Deniz M, Torun A, Akçabay Ç, Güzelçiçek A. Toxoplasmosis: A timeless challenge for pregnancy. *Trop Med Infect Dis* 2023; 8(1): 63. <http://dx.doi.org/10.3390/tropicalmed8010063> PMID: 36668970
- [177] Montoya JG, Laessig K, Fazeli MS, et al. A fresh look at the role of spiramycin in preventing a neglected disease: Meta-analyses of observational studies. *Eur J Med Res* 2021; 26(1): 143. <http://dx.doi.org/10.1186/s40001-021-00606-7> PMID: 34895348
- [178] Prasil P, Sleha R, Kacerovsky M, Bostik P. Comparison of adverse reactions of spiramycin versus pyrimethamine/sulfadiazine treatment of toxoplasmosis in pregnancy: Is spiramycin really the drug of choice for unproven infection of the fetus? *J Matern Fetal Neonatal Med* 2023; 36(1): 2215377. <http://dx.doi.org/10.1080/14767058.2023.2215377> PMID: 37217458
- [179] Jasper S, Vedula SS, John SS, Horo S, Sepah YJ, Nguyen QD. Corticosteroids as adjuvant therapy for ocular toxoplasmosis. *Cochrane Libr* 2017; 2017(1): CD007417. <http://dx.doi.org/10.1002/14651858.CD007417.pub3> PMID: 28125765
- [180] Hill DE, Dubey JP. *Toxoplasma gondii* as a parasite in food: Analysis and control. *Microbiol Spectr* 2016; 4(4): 4.4.64. <http://dx.doi.org/10.1128/microbiolspec.PFS-0011-2015> PMID: 27726776
- [181] Mirza Alizadeh A, Jazaeri S, Shemshadi B, et al. A review on inactivation methods of *Toxoplasma gondii* in foods. *Pathog Glob Health* 2018; 112(6): 306-19. <http://dx.doi.org/10.1080/20477724.2018.1514137> PMID: 30346249
- [182] Rostkowska C, Mota CM, Oliveira TC, et al. Si-accumulation in *artemisia annua* glandular trichomes increases artemisinin concentration, but does not interfere in the impairment of *toxoplasma gondii* growth. *Front Plant Sci* 2016; 7: 1430. <http://dx.doi.org/10.3389/fpls.2016.01430> PMID: 27721819
- [183] Sakikawa M, Noda S, Hanaoka M, et al. Anti-Toxoplasma antibody prevalence, primary infection rate, and risk factors in a study of toxoplasmosis in 4,466 pregnant women in Japan. *Clin Vaccine Immunol* 2012; 19(3): 365-7. <http://dx.doi.org/10.1128/0144-5498.011-2015> PMID: 22205659
- [184] Al-Sheyab NA, Obaidat MM, Bani Salman AE, Lafi SQ.

- Toxoplasmosis-related knowledge and preventive practices among undergraduate female students in Jordan. *J Food Prot* 2015; 78(6): 1161-6.
<http://dx.doi.org/10.4315/0362-028X.JFP-14-579> PMID: 26038907
- [185] Liu Q, Singla LD, Zhou H. Vaccines against *Toxoplasma gondii* : Status, challenges and future directions. *Hum Vaccin Immunother* 2012; 8(9): 1305-8.
<http://dx.doi.org/10.4161/hv.21006> PMID: 22906945
- [186] Bobić B, Villena I, Stillwaggon E. Prevention and mitigation of congenital toxoplasmosis. Economic costs and benefits in diverse settings. *Food Water Parasitol* 2019; 16: e00058.
<http://dx.doi.org/10.1016/j.fawpar.2019.e00058> PMID: 32095628
- [187] Chu KB, Quan FS. Advances in *toxoplasma gondii* vaccines: current strategies and challenges for vaccine development. *Vaccines* 2021; 9(5): 413.
<http://dx.doi.org/10.3390/vaccines9050413> PMID: 33919060